

Aggressive Metastatic Translocation Renal Carcinoma in a 23-year-old Man

Nabeel Sarwani, David S. Hartman

Translocation renal carcinomas are a rare subtype of renal cell carcinoma that typically occurs in young patients, especially those who have received prior chemotherapy. We present the case of a 23-year-old man with abdominal pain, nausea vomiting and neck swelling. Contrast enhanced computed tomography (CECT) of the neck, chest, abdomen and pelvis showed extensive left supraclavicular adenopathy, as well as extensive retroperitoneal adenopathy, displacing the pancreas superiorly, as well as encasing the aorta.

Case Report

The patient is a 23-year-old man who presented with abdominal pain, nausea, vomiting and neck swelling. Contrast enhanced computed tomography (CECT) of the neck, chest, abdomen and pelvis was performed and showed extensive left supraclavicular adenopathy, as well as extensive retroperitoneal adenopathy, displacing the pancreas superiorly, and encasing the aorta (Figures 1 and 2). There were no pulmonary, chest wall or renal fossa masses. Biopsy of the retroperitoneal adenopathy demonstrated metastatic mixed papillary and clear cell renal cell carcinoma, Fuhrman Grade 3, with Xp11 translocation.

At the age of three, the patient was diagnosed with a chest wall primitive neuroectodermal tumor (PNET) (Askin Tumor). This tumor was resected and treated with chemotherapy (adriamycin and cyclophosphamide), and subsequent radiotherapy. After treatment, there was no evidence of recurrence or metastases. He remained in remission, until the age of eight, at which time he was discovered to have a right renal mass, which was treated by radical

nephrectomy. The tumor had invaded into the renal pelvis, and adjacent lymph nodes were positive for metastasis. On microscopic examination the tumor was a mixed papillary and clear cell renal cell carcinoma, Fuhrman Grade 3, and was later documented to have Xp11 translocation by fluorescence in situ hybridization (FISH) technique. No

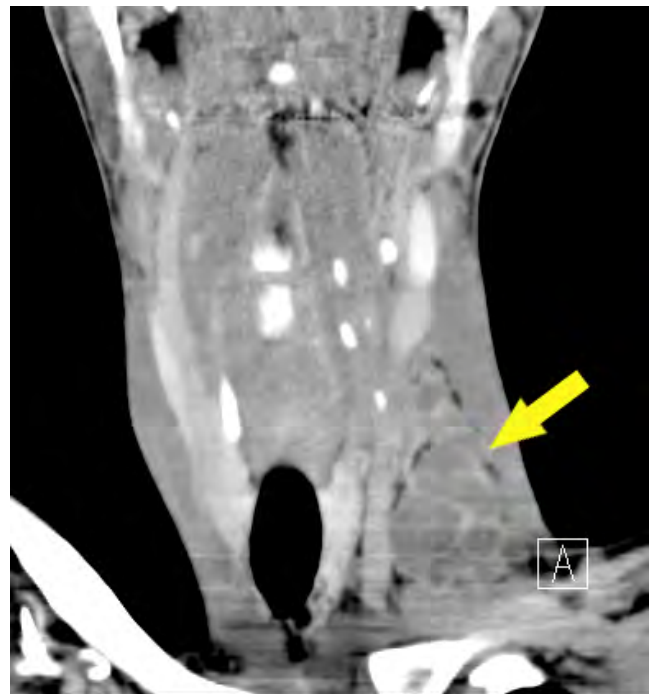

Figure 1. Coronally reformatted CECT of the neck demonstrates multiple areas of necrotic, left supraclavicular lymphadenopathy.

Citation: Sarwani N, Hartman DS. Aggressive metastatic translocation renal carcinoma in a 23-year-old man. *Radiology Case Reports*. [Online] 2007;2:50.

Copyright: © 2007 Nabeel Sarwani. This is an open-access article distributed under the terms of the Creative Commons Attribution-NonCommercial-NoDerivs 2.5 License, which permits reproduction and distribution, provided the original work is properly cited. Commercial use and derivative works are not permitted.

Abbreviations: CECT, contrast enhanced computed tomography, CT, computed tomography, PNET, primitive neuroectodermal tumor, FISH, fluorescence in situ hybridization.

Nabeel Sarwani (Email: nsarwani@hmc.psu.edu) and David S. Hartman are from the Department of Radiology, Penn State Milton S. Hershey Medical Center, Hershey, PA, United States of America.

Published: June 6, 2007
DOI: 10.2484/rcr.v2i2.50

Aggressive Metastatic Translocation Renal Carcinoma in a 23-year-old Man

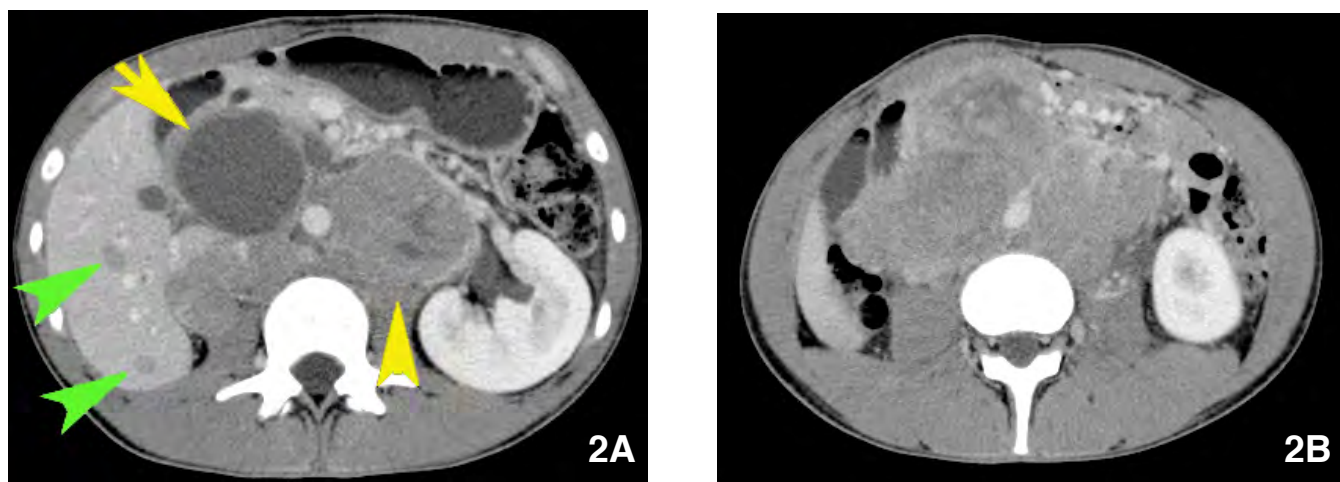


Figure 2. A. Axial CECT of the upper abdomen demonstrates multiple hepatic metastases (green arrowheads), with a large area of necrotic subhepatic lymphadenopathy (yellow arrow), and bulky paraortic disease (yellow arrowhead). **B.** Axial CECT at a lower level again demonstrates extensive, bulky retroperitoneal lymphadenopathy, encasing the aorta, and displacing the bowel anteriorly.

documentation of adjuvant therapy was given at that time, and the patient was lost to follow up until this admission. The patient is currently alive, on palliative care, as there is presently no well-established therapeutic regimen for this entity.

Discussion

Translocation renal carcinoma is a rare subtype of renal cell carcinoma that typically occurs in young patients, especially those who have received prior chemotherapy (1). The list of agents include, but is not limited to, cyclophosphamide, cytosine arabinoside, daunorubicin, etoposide and vincristine, and may have been given for neoplastic or autoimmune diseases. These neoplasms may be extremely aggressive (2), but due to their relative rarity, their imaging findings have been incompletely described, with only the primary renal lesion previously imaged (3). The imaging findings in our patient were more consistent with neuroblastoma or lymphoma than with those typically seen with renal cell carcinoma (e.g. pulmonary and bone metastases).

When a mass is detected in a patient with a past history of a childhood malignancy or autoimmune disease treated with chemotherapy, the radiologist should be aware of the possibility that the mass represents an Xp11 translocation renal carcinoma. Although initial clinical studies suggest an indolent course(4), this rare subtype of renal carcinoma may present as diffuse, extensive, atypical metastatic disease, resembling lymphoma or neuroblastoma.

References

1. Argani P, Lae M, Ballard ET, et al. Translocation carcinomas of the kidney after chemotherapy in childhood. *J Clin Oncol.* 2006 Apr 1;24(10):1529-34. [[PubMed](#)]

2. Argani P, Ladanyi M. Recent advances in pediatric renal neoplasia. *Adv Anat Pathol.* 2003 Sep;10(5):243-60. [[PubMed](#)]

3. Fenton DS, Taub JW, Amundson GM, Padiyar NP, Cushing B. Renal cell carcinoma occurring in a child 2 years after chemotherapy for neuroblastoma. *AJR.* 1993; 161: 165-166. [[PubMed](#)]

4. Eble JN, Sauter G, Epstein JI, Sesterhenn IA, eds. *Pathology and genetics of tumours of the urinary system and male genital organs.* Lyon, France: IARC Press, 2004.