

A Toddler with Bilateral Fractures of the Fibula

Tamara Miner Haygood, Ph.D., M.D., Jason Wong, M.D., Rajendra Kumar, M.D., F.A.C.R., and Susan John, M.D., F.A.C.R.

Stress fractures are uncommon, and bilateral stress fractures are rare. The diagnosis of stress fracture can be difficult as conventional radiographs usually show evidence of the fracture repair instead of the fracture. A stress fracture must be differentiated from more serious processes, particularly osteomyelitis and bone malignancies. In young children there may be no obvious cause, and imaging can greatly facilitate the diagnosis. We present a case of a toddler referred for evaluation for a possible bone malignancy but who was diagnosed with bilateral fibular stress fractures. Only one case of bilateral fibular stress fracture has been described in a toddler. However, unlike this case, our patient lacked an apparent explanation for the injury.

Introduction

Stress fractures are believed to be due to repeated stress endured by the bone rather than an acute traumatic event [1]. They can occur in athletes likely because of the repeated stress endured by the bones with activity. In toddlers, these fractures are often associated with the beginning of ambulation, probably because the weight-

bearing bones have not yet adjusted to the novel stresses related to walking [2, 3].

Overall, stress fractures are uncommon: even in young athletes, stress fractures make up only 1.5-3.4% of all overuse injuries [4, 5]. After the tibia, the fibula is the most common site of stress fractures, comprising up to 30% of all stress fractures in athletes [6] and about 20-30% of stress fractures in young children [7, 8].

In this paper, we describe bilateral fibular stress fractures in a two-and-a-half-year-old boy. With the exception of a case report of repeated trauma by a walker [9], bilateral fibular stress fractures have only been reported in adolescents [10, 11], usually as a result of athletics.

Case Report

In mid-November, a toddler boy, then 26 months old, began to limp on his right leg. Physical examination by his pediatrician produced no abnormal findings, and he was sent home. However, the child continued to limp, and at the end of November, he began to complain of tenderness when his right leg was touched.

Citation: Haygood TM, Wang J, Kumar R, John S. A toddler with bilateral fractures of the fibula. *Radiology Case Reports*. [Online] 2009;4:300.

Copyright: © 2009 The Authors. This is an open-access article distributed under the terms of the Creative Commons Attribution-NonCommercial-NoDerivs 2.5 License, which permits reproduction and distribution, provided the original work is properly cited. Commercial use and derivative works are not permitted.

Abbreviations: MRI, magnetic resonance imaging

Tamara Miner Haygood, Ph.D., M.D. (Email: tamara.haygood@mdanderson.org), and Rajendra Kumar, M.D., are in the Department of Diagnostic Radiology, University of Texas M. D. Anderson Cancer Center, Houston, Texas, United States of America.

Jason Wong (Email: Jwong14@rocketmail.com), is at the University of Alberta, Edmonton, Alberta, Canada.

Susan John, M.D., F.A.C.R. (Email: susan.d.john@uth.tmc.edu), is at the University of Texas Medical School, Houston, Texas, United States of America.

Published: June 21, 2009

DOI: 10.2484/rcr.v4i2.300

A Toddler with Bilateral Fractures of the Fibula

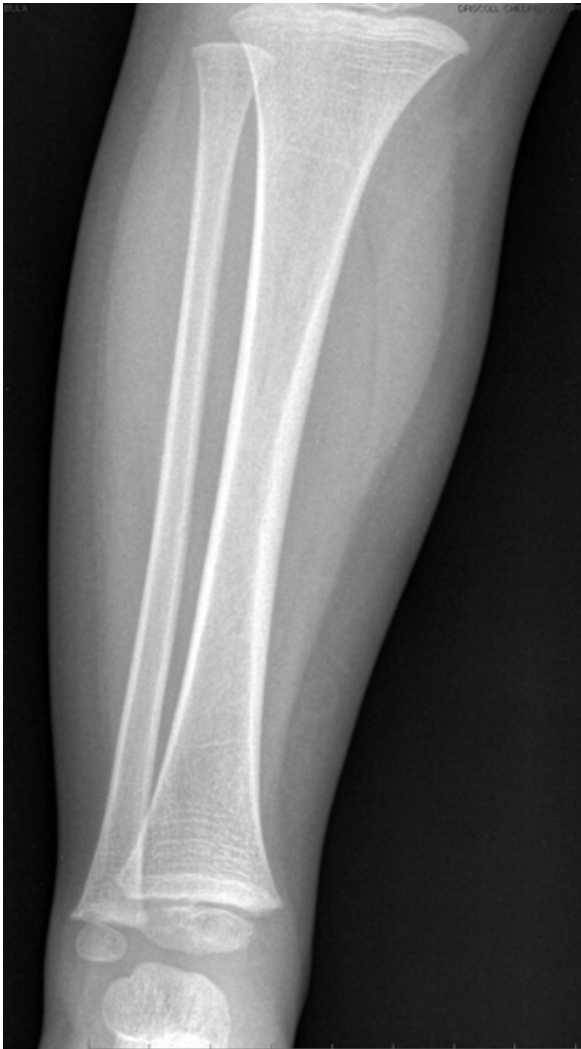

Figure 1. 26-month-old boy with limp. AP radiograph of right tibia and fibula is normal.

These symptoms resolved after several days, and his gait returned to normal by the beginning of December, though he had brief, intermittent spells of limping later that month. A month later, on 9 January, he again began limping, this time on his left leg. Conventional radiographs revealed no abnormalities (Figure 1). A bone scan demonstrated distinctly increased activity in the mid-fibular diaphysis bilaterally (Figure 2).

Several days later, the toddler tripped and fell. He was brought into the emergency department because of refusal to walk. Conventional radiographs in the emer-

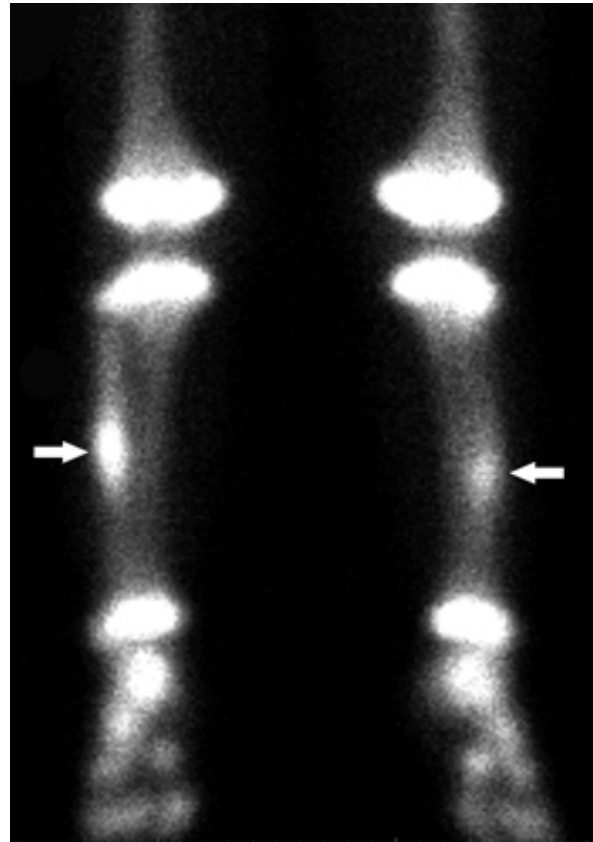


Figure 2. 26-month-old boy with limp. Delayed image of nuclear bone scan demonstrates focal abnormal activity in the mid-diaphysis of each fibula (arrows). Activity about the joints is normal.

gency department were reportedly normal. The following day, on 18 January, the patient was sent for magnetic resonance imaging (MRI), which demonstrated thickening of the cortices of the mid-fibular diaphyses bilaterally. A fracture line was also seen on the sagittal view (Figure 3).

The patient's pain and limp resolved temporarily in early February but he soon began to complain of arm pain and night sweats. He was therefore referred to our institution for a second opinion and possible evaluation and biopsy for Langerhans cell histiocytosis or a bone malignancy.

In hospital the child, then 30 months old, was not limping and was running around the examining room. There was no focal tenderness in either lower extremity

A Toddler with Bilateral Fractures of the Fibula

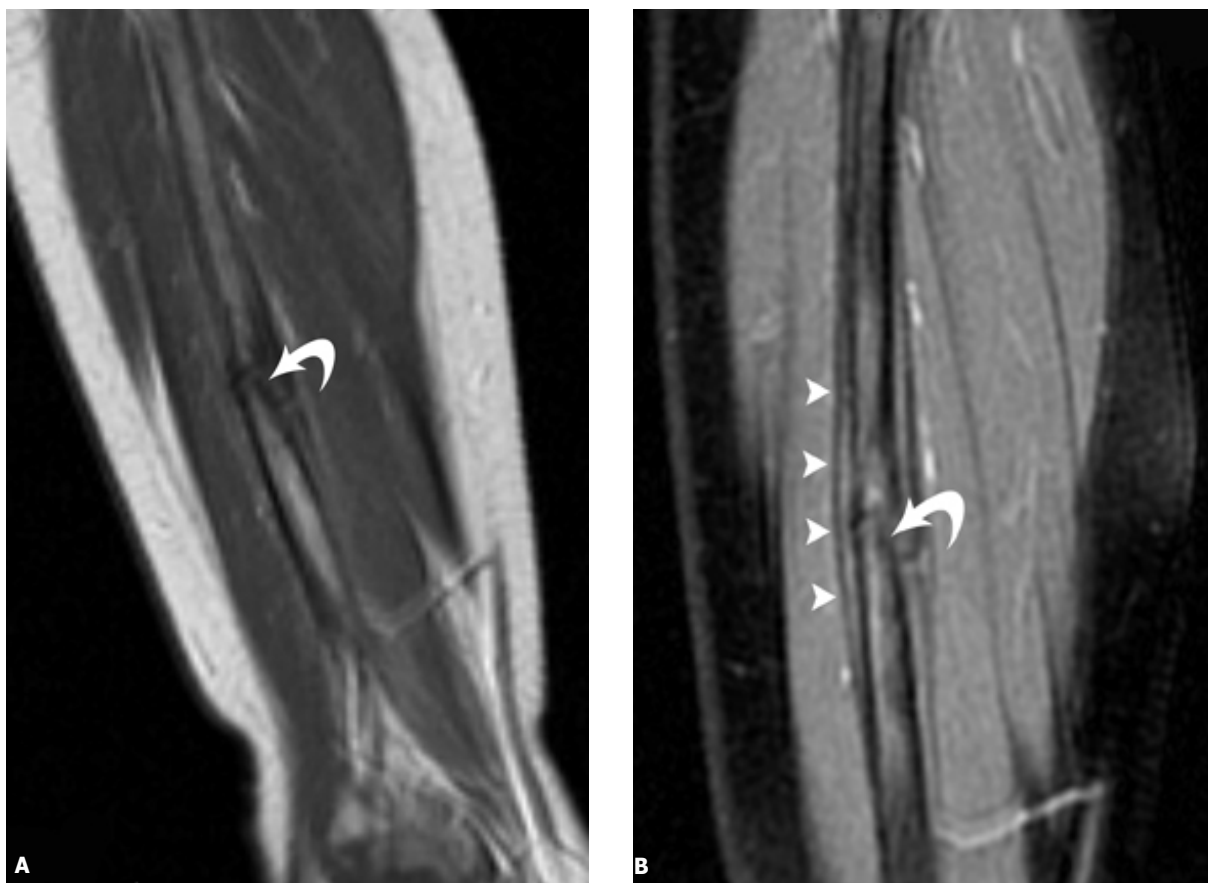


Figure 3. 26-month-old boy with limp and subsequent fall. **A**, Sagittal TI-weighted (383/a) spin echo MRI of left fibula demonstrating a fracture line (curved arrow). **B**, Sagittal proton-density weighted (2500/29) fast spin echo (ETL6) MRI of the left fibula again demonstrating the fracture line (curved arrow) as well as periosteal elevation (arrowheads). This appearance is quite diagnostic of fracture.

or any palpable masses or nodules. All joints demonstrated normal range of motion, and he had normal muscle tone and above average muscle strength. There was no ecchymosis or skin discoloration.

Radiographs obtained in conjunction with this visit demonstrated thickened periosteal new bone primarily along the lateral cortex of each fibula. In addition, there was a faint fracture line through the involved cortex of the right fibula (Figure 4). There was no additional soft-tissue mass as might be expected with tumor. There was also no focal fluid collection, sinus track, or sequestrum as might be present with osteomyelitis. Ultimately, the

patient's clinical improvement, along with the absence of concerning features on imaging, supported the diagnosis of healing stress fractures over other serious diseases.

Discussion

Diagnosis of a stress fracture can be difficult because there is often no obvious history of trauma or unusual activity. In addition, young children often have vague presentations, most commonly a limp or refusal to bear weight, usually accompanied by pain and local tenderness. Radiographs in early stages tend to be normal. Later during the healing phase periosteal new bone and

A Toddler with Bilateral Fractures of the Fibula

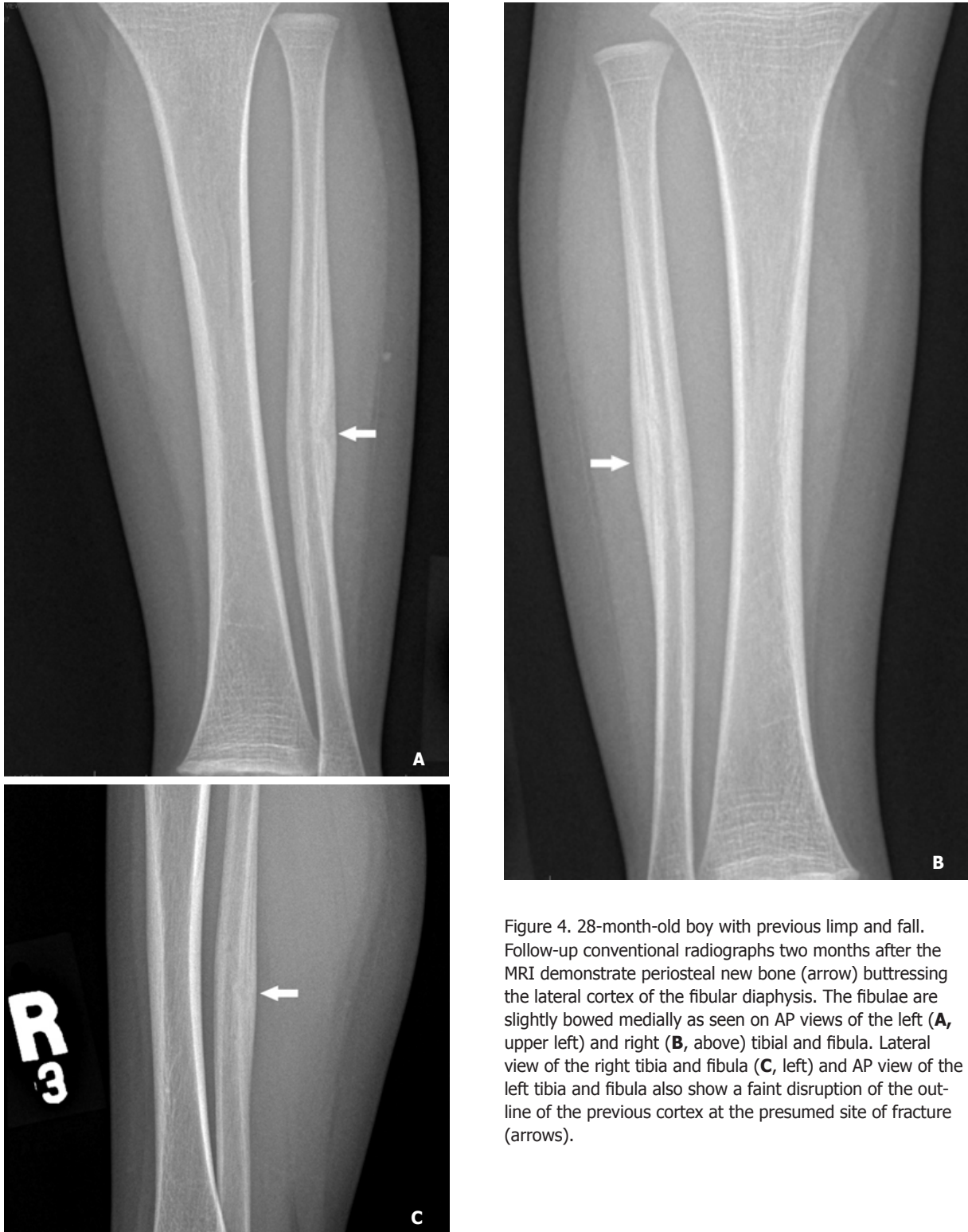

Figure 4. 28-month-old boy with previous limp and fall. Follow-up conventional radiographs two months after the MRI demonstrate periosteal new bone (arrow) buttressing the lateral cortex of the fibular diaphysis. The fibulae are slightly bowed medially as seen on AP views of the left (**A**, upper left) and right (**B**, above) tibia and fibula. Lateral view of the right tibia and fibula (**C**, left) and AP view of the left tibia and fibula also show a faint disruption of the outline of the previous cortex at the presumed site of fracture (arrows).

A Toddler with Bilateral Fractures of the Fibula

perhaps a fracture line become evident. The abundant callus formed by healing bone in young children can mimic other causes of periosteal new bone, particularly tumor and infection [12].

Even if the radiographs are normal in early stages of stress fractures, the radionuclide bone scan invariably shows focal increased radiotracer uptake at the sites of these fractures [13].

Extremity pain, local tenderness, and a triad of bowed fibula, periosteal thickening, and a transverse area of radiolucency and/or sclerosis on radiographs indicate a fibular stress fracture. In cases where the diagnosis of stress fracture is unclear, it is prudent to observe the child for resolution of the pain and follow up with a conventional radiograph after 7-10 days [14]. Alternatively, a more detailed history and serial X-rays over a short time span may suggest the diagnosis of a stress fracture [3]. However, in very young children who cannot provide a detailed history and whose parents or caregivers may not have noticed any activity they consider unusual, it can be difficult to differentiate the exuberant callus of a healing stress fracture from osteomyelitis or tumor [7]. MRI can then allow the diagnosis to be made by directly demonstrating the fracture line before it becomes visible on conventional radiographs [12].

We have found only one other case of bilateral fibular stress fractures in the literature. In this case, the authors described a toddler who repeatedly banged her infant walker into the kitchen cabinets. The authors attributed the fracture to repeated, subacute trauma to the fibulae as the force from the collision was transferred to the bone via the walker [9]. However, this mechanism would not explain the stress fractures in our patient as he was already ambulating and not using a walker.

Alternatively, fibular stress fractures in children may be a result of excessive axial loading—that is, excessive vertical force along the long axis of the bone [15]. The tibia supports the majority of the child's weight, but in cases of overweight children, for example, the fibula may be required to consistently bear a greater load. In addition, the fibula may be stressed by the activity of attached muscles [16]. The gracile shape of the fibula may also increase the susceptibility of the fibula to bowing fractures [15], and in fact, delayed radiographs of the fibula of our patient show an increased medial curvature (see Figure 4 above). The exact mechanism of injury for most stress fractures in toddlers remains unclear, and this lack of an obvious cause is one of the challenges to

diagnosis. Ultimately, our patient's injuries were probably related to the stresses of weight bearing.

In summary, this case is, to our knowledge, the first case of bilateral mid-diaphyseal fibular fractures in a toddler presenting without specific recognized trauma or other predisposing cause. The conventional radiographs on presentation were normal, and diagnosis was established by follow-up radiographs, nuclear bone scan, and MRI.

References

1. Keret D, Segev E, Hayek S, et al. Bilateral symmetric stress fractures in a toddler. *J Pediatr Orthop B*. 2001; 10(1):73-7. [PubMed]
2. Donnelly LF. Toddler's fracture of the fibula. *Am J Roentgenol*. 2000; 175:922. [PubMed]
3. Engh CA, Robinson RA, Milgram J. Stress fractures in children. *J Trauma*. 1970; 10(7):532-41. [PubMed]
4. Watkins J, Peabody P. Sports injuries in children and adolescents treated at a sports injury clinic. *J Sports Med Phys Fitness*. 1996; 36(1):43-8. [PubMed]
5. Baxter-Jones A, Maffulli N, Helms P. Low injury rates in elite athletes. *Arch Dis Child*. 1993; 68(1):130-2. [PubMed]
6. Bennell KL, Brukner PD. Epidemiology and site specificity of stress fractures. *Clin Sports Med*. 1997; 16(2):179-96. [PubMed]
7. Walker RN, Green NE, Spindler KP. Stress fractures in skeletally immature patients. *J Pediatr Orthop*. 1996; 16(5):578-84. [PubMed]
8. Devas MB. Stress fractures in children. *J Bone Joint Surg Br*. 1963; 45:528-41. [PubMed]
9. Sheehan KM, Gordon S, Tanz RR. Bilateral fibula fractures from infant walker use. *Pediatr Emerg Care*. 1995; 11(1):27-9. [PubMed]
10. Lehman TP, Belanger MJ, Pascale MS. Bilateral proximal third fibular stress fractures in an adolescent

A Toddler with Bilateral Fractures of the Fibula

female track athlete. *Orthopedics*. 2002; 25(3):329-32. [PubMed]

11. Peiro V, Herrador MA, Leyes M, Guillen P. Bilateral stress fracture of the proximal fibula in a young soccer player on bone scanning. *Clin Nucl Med*. 2003; 28(1):49-51. [PubMed]

12. Castillo M, Tehranzadeh J, Morillo G. Atypical healed stress fracture of the fibula masquerading as chronic osteomyelitis. A case report of magnetic resonance distinction. *Am J Sports Med*. 1988; 16(2):185-8. [PubMed]

13. Kozłowski K, Urbonaviciene A. Stress fractures of the fibula in the first few years of life (report of six cases). *Australas Radiol*. 1996; 40(3):261-3. [PubMed]

14. Kozłowski K, Azouz M, Hoff D. Stress fracture of the fibula in the first decade of life. Report of eight cases. *Pediatr Radiol*. 1991; 21(5):381-3. [PubMed]

15. John SD, Moorthy CS, Swischuk LE. Expanding the concept of the toddler's fracture. *Radiographics*. 1997; 17(2):367-76. Link to PubMed Abstract: <http://www.ncbi.nlm.nih.gov/pubmed/9084078?dopt=Abstract>

16. Burrows HJ. Fatigue fractures of the fibula. *J Bone Joint Surg Am*. 1948; 30B(2):266-79. Link to PubMed Abstract: <http://www.ncbi.nlm.nih.gov/pubmed/18861065?dopt=Abstract>