

Reduction of Small Bowel Intussusception Caused by Jejunal Hamartomatous Polyps Documented by Intraoperative Video

Mahesh M. Thapa, M.D., Sumit Pruthi, M.D., Gisele E. Ishak, M.D., and Randolph Otto, M.D.

We present a case of non-Peutz Jegher hamartomatous polyps causing jejuno-jejunal intussusception and small bowel obstruction in a pediatric patient. In addition, we also provide an intraoperative video of the intussusception reduction process. Polyps causing small bowel intussusception are uncommon but not rare. However, we could not find in the medical literature any videos of the intussusception reduction process. We feel this case report, the discussion provided, and the intraoperative video correlation will offer a unique educational perspective to this disease entity. In addition, this case report will also show the importance of considering small bowel intussusception in the differential of a child who presents with vague but persistent abdominal symptoms.

Introduction

We present a case of non-Peutz Jegher hamartomatous polyps causing jejuno-jejunal intussusception and small bowel obstruction in a pediatric patient. In addition, we also provide an intraoperative video of the intussusception reduction process. Polyps causing small

bowel intussusception are uncommon but not rare. However, we could not find in the medical literature any videos of the intussusception reduction process. We feel this case report, the discussion provided, and the intraoperative video correlation will offer a unique educational perspective to this disease entity. In addition, this case report will also show the importance of considering small bowel intussusception in the differential of a child who presents with vague but persistent abdominal symptoms.

Citation: Thapa MM, Pruthi S, Ishak GE, Otto R. Reduction of small bowel intussusception caused by jejunal hamartomatous polyps documented by intraoperative video. *Radiology Case Reports*. [Online] 2009;4:292.

Copyright: © 2009 The Authors. This is an open-access article distributed under the terms of the Creative Commons Attribution-NonCommercial-NoDerivs 2.5 License, which permits reproduction and distribution, provided the original work is properly cited. Commercial use and derivative works are not permitted.

Abbreviations: CT, computed tomography

Mahesh M. Thapa, M.D. (Email: thapamd@u.washington.edu), Sumit Pruthi, M.D., Gisele E. Ishak, M.D., and Randolph Otto, M.D., are in the Department of Radiology, Seattle Children's Hospital and University of Washington School of Medicine, Seattle, WA 98105, United States of America.

Published: May 31, 2009

DOI: 10.2484/rcr.v4i2.292

Case Report

A four-year-old boy presented to the emergency room with a history of episodic abdominal pain that was quite severe in nature. He also had recent history of bilious vomiting. There was no history of diarrhea or constipation. He had had two previous evaluations for intermittent abdominal pain, which had resolved

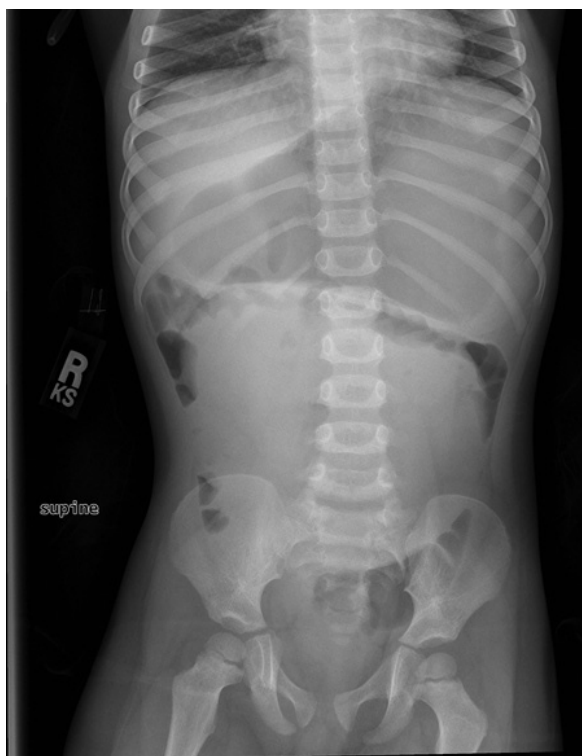

Figure 1. 4-year-old boy with small bowel polyps. Frontal, supine radiograph of the abdomen demonstrates a large soft tissue mass in the central abdomen, displacing bowel loops peripherally. The stomach is moderately distended.

without intervention. On the current visit, physical exam revealed a very firm and full abdomen. Oral mucosa was without pigmented lesions. Family history was noncontributory. Laboratory evaluation revealed a mild leukocytosis.

Frontal radiograph of the abdomen (Fig. 1) demonstrated a mid abdominal soft tissue mass which displaced bowel loops to the periphery, a distended stomach, and a relative paucity of gas distally. A small bowel obstruction was suspected and an abdominal/pelvic contrast enhanced computed tomography (CT) scan (Fig. 2) was performed. The CT scan revealed a small bowel to small bowel intussusception and obstruction. The intussusciens was maximally dilated to 5 cm. Patient was then taken to the operating room. On entering the peritoneal cavity, very large, distended loops of small bowel were encountered (Fig. 3). There was proximal jejunal to jejunal intussusception (Figure 4) with lead

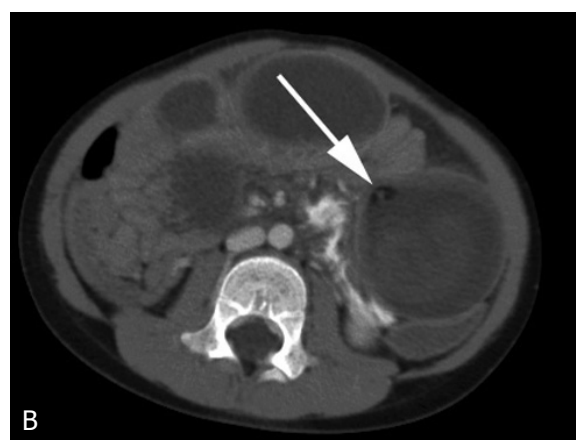
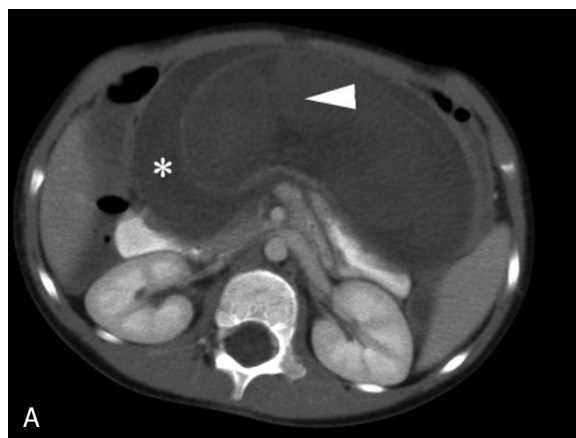

Figure 2. 4-year-old boy with small bowel polyps. Contrast enhanced axial CT images demonstrate the jejunojejunal intussusception. **A**, The intussusceptum (arrow head) is contained within the intussusciens (*). **B**, Intussuscepted mesenteric fat can also be identified (arrow).

point about 12 cm distal to the ligament of treitz.

Through a combination of careful compression (“milking”) distally and gentle traction proximally, the intussusception was reduced (Video 1). There were three polyps noted on the antimesenteric border of the jejunum that acted as a lead point (Fig. 5). Almost half of the small bowel was edematous with hemorrhagic-appearing mucosa. This intussusception involved nearly half of the length of the small bowel prior to reduction. After complete reduction, there was a clear transition zone between the proximal 10 cm of the jejunum and the next 50 cm, where there was hemorrhagic-appearing

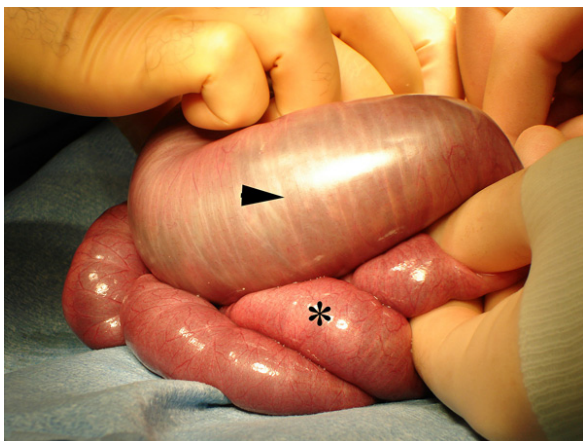


Figure 3. 4-year-old boy with small bowel polyps. Upon entering the peritoneal cavity, some distended loops of jejunum were identified (arrowhead). More normal appearing bowel is also identified (*). Note the difference not only in size, but also the color.

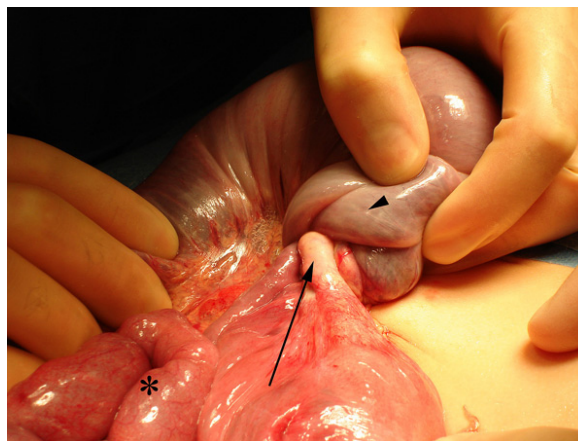


Figure 4. 4-year-old boy with small bowel polyps. Intraoperative view of the intussusception with normal appearing bowel (*) distally, intussusceptum which includes mesenteric fat (arrow), and dilated intussusciptum (arrow head).

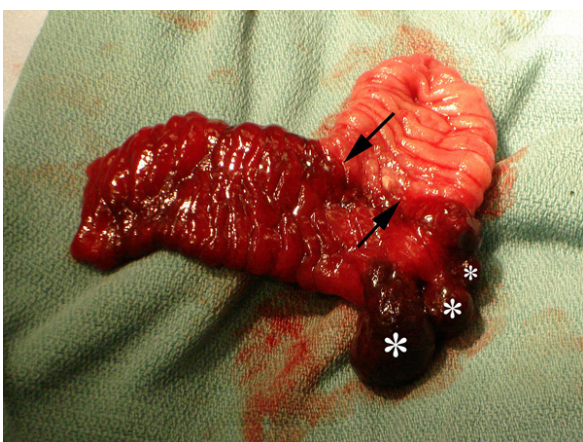


Figure 5. 4-year-old boy with small bowel polyps. Gross, resected jejunal specimen with three hemorrhagic polyps (*) which served as the lead points. Note the clear demarcation between the hemorrhagic and normal mucosa (arrows).

mucosa (Figure 5). A 6 cm segment of the jejunum containing the polyps was resected. Primary end-to-end anastomosis was then performed. The remainder of bowel was then palpated, and no additional polyps were noted. Pathological evaluation revealed hemorrhagic hamartomatous polyps (Fig. 6).

Video 1

Video 1. 4-year-old boy with small bowel polyps. Intraoperative video of successful reduction of jejuocolic intussusception.

Discussion

Intussusception is a common cause of abdominal emergency and intestinal obstruction in childhood [1]. Approximately 90% of all pediatric intussusceptions are ileocolic, ileocecal, or ileoileocolic. Pathologic lead points, such as Meckel's diverticulum, polyp or lymphoid hyperplasia are identified in less than 10% of cases [2, 3]. Relative to the pediatric population, intussusception is uncommon in adults, but greater than 60% of cases involve the small bowel and 90% of cases have a definite lead point [2]. In contrast, small bowel intussusception with lead point is uncommon in children. Puri and Guiney reported that out of 292 children with intussusception, only 10 (3.5%) were caused by small bowel tumors [4]. Kornecki et al. examined 50 children with spontaneous reduction of intussusception and discovered 43 had small bowel intussusception. They suggested conservative management (i.e. observation) for

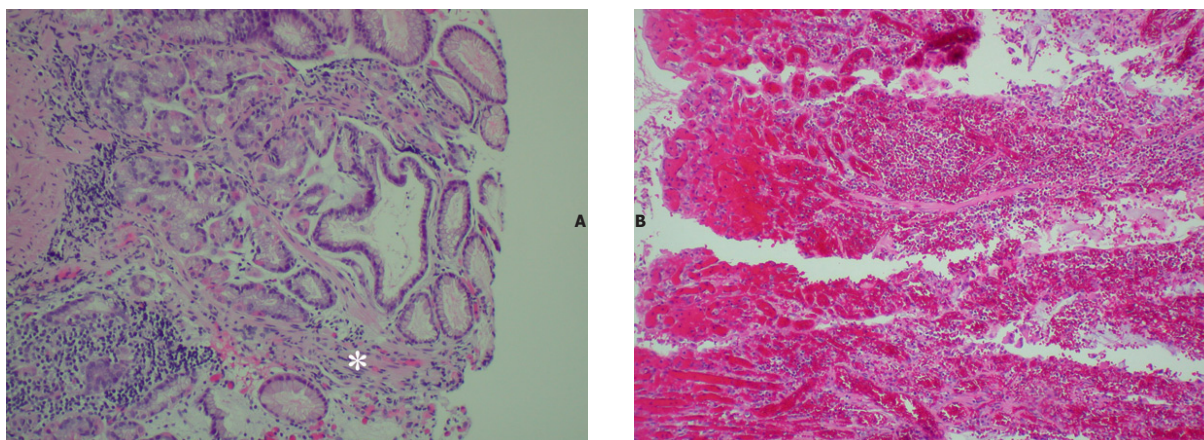


Figure 6. 4-year-old boy with small bowel polyps. Low power (A) and high power (B) H&E photos of hamartomatous polyp with hemorrhagic necrosis. Note the band of smooth muscle running through the polyp (*). Images courtesy of Dr. Kathleen Patterson.

asymptomatic patients [5]. Ko et al. recently performed a retrospective analysis on 19 symptomatic children with surgically proven small bowel intussusception, and concluded that in this patient population delayed diagnosis was very common, leading to an increased rate (42%) of bowel complications following surgery [2]. Of the 19 patients, 4 (21%) had jejuno-jejunal SBI, 2 of which were caused by hamartomatous polyps [2].

Hamartomas are tumors representing anomalous development of tissues natural to an organ. Hamartomatous polyps in the GI tract are a frequent cause of intussusception and often occur in the setting of Peutz-Jeghers Syndrome. In fact, hamartomatous polyps are found in nearly all patients with Peutz-Jeghers Syndrome [6]. The patient in our case report had neither the characteristic mucocutaneous melanin pigmentation, nor a family history of Peutz-Jeghers Syndrome. Therefore he did not fit the criteria of the syndrome suggested by Giardiello et al. [7].

The purpose of this case report is two fold. First, we want to emphasize that small bowel intussusception can present with vague abdominal symptoms, which frequently leads to a delay in diagnosis and emergent surgical intervention. While asymptomatic patients can probably be observed, symptomatic patients will often need surgical intervention. Second, we present an intraoperative video of the small bowel intussusception reduction process, which has not been shown in the medical literature, to the best of our knowledge. We

believe this video offers a unique educational perspective on this pathologic process.

References

1. Yamagami T, Tokiwa K, Iwai N. Myoepithelial hamartoma of the ileum causing intussusception in an infant. *Pediatr Surg Int* 1997 Mar 21;12(2/3):206-7. [PubMed]
2. Ko SF, Lee TY, Ng SH, et al. Small bowel intussusception in symptomatic pediatric patients: experiences with 19 surgically proven cases. *World J Surg* 2002 Apr;26(4):438-43. [PubMed]
3. Ikegami R, Watanabe Y, Tainaka T. Myoepithelial hamartoma causing small-bowel intussusception: a case report and literature review. *Pediatr Surg Int* 2006 Apr;22(4):387-9. [PubMed]
4. Puri P, Guiney EJ. Small bowel tumours causing intussusception in childhood. *Br J Surg* 1985 Jun;72(6):493-4. [PubMed]
5. Kornecki A, Daneman A, Navarro O, et al. Spontaneous reduction of intussusception: clinical spectrum, management and outcome. *Pediatr Radiol* 2000 Jan;30(1):58-63. [PubMed]

Reduction of Small Bowel Intussusception Caused by Jejunal Hamartomatous Polyps... with Intraoperative Video

6. Choi HS, Park YJ, Park JG. Peutz-Jeghers syndrome: a new understanding. *J Korean Med Sci* 1999 Feb;14(1):2-7. [PubMed]
7. Giardiello FM, Welsh SB, Hamilton SR, et al. Increased risk of cancer in the Peutz-Jeghers syndrome. *N Engl J Med* 1987 Jun;11:316(24):1511-4. [PubMed]