

Extrahepatic Portal Vein Aneurysm

Ron C. Gaba, M.D., Julian D. Hardman, M.D., and Sonia J. Bobra, M.D.

Portal vein aneurysms are rare vascular abnormalities, many of which are incidentally discovered on routine imaging studies. The etiology of portal venous aneurysms is poorly understood, and the management of these lesions is debatable. We report the case of a 61-year-old woman with extrahepatic portal vein aneurysm. We review the nature and significance of this abnormality and discuss appropriate clinical, imaging, and treatment approaches.

Introduction

True venous aneurysms are uncommon abnormalities [1], and portal venous aneurysms are even rarer, representing less than 3% of all venous aneurysms [2]. Due to their infrequency, there is no literature consensus on the etiology, appropriate management, and clinical and imaging follow-up of portal vein aneurysms. The greater utilization of abdominal cross-sectional imaging in recent years has led to a growing number of cases describing portal vein aneurysm [3-9], and as such, proper handling of this lesion is increasingly relevant to both

diagnostic and interventional radiologists. As such, we present the case of a 61-year-old patient with no history of liver disease and a portal vein aneurysm incidentally found on abdominal CT examination, and review the nature, significance, treatment strategies, and imaging surveillance of this vascular abnormality.

Case Report

Institutional review board approval is not required for single retrospective case studies at our hospital. A 61-year-old woman with a past medical history of surgically resected squamous cell carcinoma of the right fifth digit and vulvar carcinoma in situ underwent routine surveillance colonoscopy for colorectal carcinoma screening at an outside hospital. Endoscopy revealed a small mass in the ascending colon, which biopsy showed to represent a tubulovillous adenoma. A laparoscopic right hemicolectomy was subsequently performed. The patient's post-operative course was complicated by an episode of small bowel obstruction diagnosed by abdominal computed tomography (CT) (Fig. 1). The patient responded well to conservative management of the small bowel obstruction, and was subsequently dis-

Citation: Gaba RC, Hardman JD, Bobra SJ. Extrahepatic Portal Vein Aneurysm. *Radiology Case Reports*. [Online] 2009;4:291.

Copyright: © 2009 The Authors. This is an open-access article distributed under the terms of the Creative Commons Attribution-NonCommercial-NoDerivs 2.5 License, which permits reproduction and distribution, provided the original work is properly cited. Commercial use and derivative works are not permitted.

Abbreviations: CT, computed tomography

Ron C. Gaba, M.D. (Email: rongaba@yahoo.com), and Sonia J. Bobra, M.D., are in the Department of Radiology, University of Illinois Medical Center at Chicago, Chicago, IL, United States of America.

Julian D. Hardman, M.D., is at the University of Illinois at Chicago School of Medicine, Chicago, IL, United States of America.

Published: June 30, 2009

DOI: 10.2484/rcr.v4i2.291

Extrahepatic Portal Vein Aneurysm

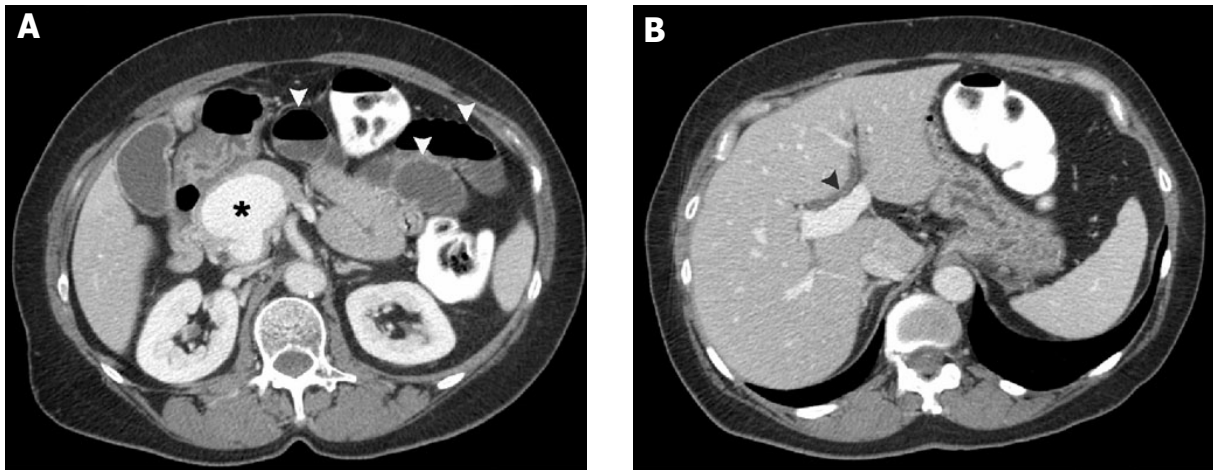


Figure 1. X-year-old man/woman with symptom lo Figure 1. 61-year-old woman with extrahepatic portal vein aneurysm. Contrast enhanced CT image (A) demonstrates small bowel obstruction, evidenced by dilated small intestinal loops with air-fluid levels (arrowheads). 5 cm diameter extrahepatic portal vein aneurysm (asterisk) located at superior mesenteric vein and splenic vein confluence. (B) Intrahepatic portal vein shows normal caliber. Mild dilation of the intrahepatic biliary system is evident (arrowhead).

charged from the hospital in good condition. However, aneurysmal dilation of the portal vein was incidentally noted at that time (Fig. 1). Given the presence of this vascular abnormality, the patient was referred to interventional radiology at our institution for assistance in further evaluation and management of the portal vein aneurysm.

On outpatient interventional radiology consultation, the patient denied symptoms of acute or chronic abdominal discomfort, jaundice, melena, hematemesis, hemochezia, nausea, or emesis. Physical assessment revealed a normal abdominal exam, without evidence of distension or tenderness, and with normal bowel sounds. No stigmata of portal venous hypertension were seen, including congestion of abdominal wall or paraumbilical veins. Laboratory examination showed normal biochemical parameters of liver function, including a normal bilirubin level. A baseline ultrasound was performed to better delineate the aneurysm, and showed no evidence of hepatic cirrhosis or intrinsic liver disease, portal hypertension, or portal vein thrombosis (Fig. 2). On further discussion, the patient recalled that she had undergone another abdominal CT approximately eight years prior at an outside hospital. This imaging study was obtained, and comparison showed no interval change in the size or contour of the portal vein aneu-

rysm. Given the lack of clinical symptoms, underlying liver disease and portal hypertension, and aneurysm stability over time, conservative management was recommended. The patient agreed with this plan, and is doing well at the time of composition of this report. She will undergo clinical follow-up as well as serial imaging with abdominal ultrasound for aneurysm surveillance.

Discussion

Portal vein aneurysm, originally described in 1956 [10], represents the most common type of visceral venous aneurysm [2]. The reported maximum diameter of the portal vein is not greater than 15 mm in healthy subjects and 19 mm in patients with hepatic cirrhosis [11]. Thus, a portal vein diameter greater than 20 mm is commonly accepted as the diagnostic standard for extrahepatic portal vein aneurysm. Intrahepatic portal vein aneurysms have no universally accepted size standard. The most common sites aneurysmal enlargement of the portal system includes the main portal vein, the confluence of the splenic and superior mesenteric veins, and intrahepatic portal vein branches at bifurcation sites [3].

The etiology of portal vein aneurysms is controversial. Postulated origins of portal vein aneurysms

Extrahepatic Portal Vein Aneurysm

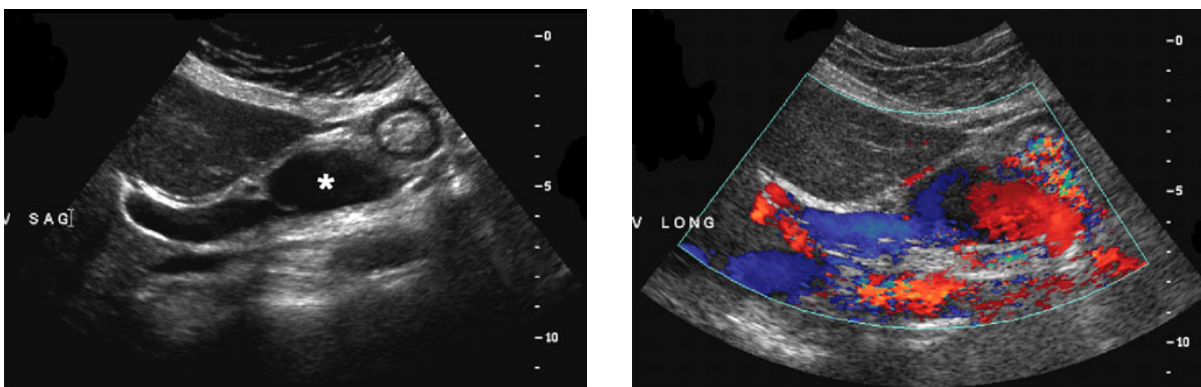


Figure 2. 61-year-old woman with extrahepatic portal vein aneurysm. Gray scale (A) and color Doppler (B) ultrasound images delineate extrahepatic location and patency of portal vein aneurysm (asterisk).

include both congenital and acquired causes. Evidence supporting a congenital cause includes reported cases of in utero diagnosis of portal vein aneurysms [12], evidence of portal venous system aneurysms in patients with histologically proven normal livers, particularly in children and young adults [3], the presence of normal portal venous pressures in the setting of portal vein aneurysm [13], and the frequent stability of aneurysms at follow-up imaging. Theories for a congenital cause involve inherent weakness in the vessel wall or incomplete regression of the distal right primitive vitelline vein leading to a vascular diverticulum that ultimately develops into an aneurysm [5]. The lack of underlying liver disease or portal hypertension, as well as aneurysm stability over time, favors a congenital cause in our case. Evidence favoring acquired causes of portal venous aneurysms is based on the greater presence of aneurysms in patients who have chronic liver disease, portal hypertension, pancreatitis, trauma, and post surgical complications [14-16]. However, because many healthy patients present incidentally and without symptoms, these factors may be contributory but not essential.

Multidetector contrast enhanced computed tomography (CT) is the imaging modality on which portal vein aneurysms are most commonly incidentally found. CT allows for precise delineation of aneurysm size and location [15]. Color Doppler sonography and magnetic resonance imaging are also accurate and reliable methods which may be used for additional diagnostic certainty [15]. The presence of an internal non-pulsatile monophasic waveform within the lesion confirms its

portal venous origin. Transjugular hepatic venography may be performed to measure hepatic venous pressures to assess for portal hypertension, and to perform liver biopsy to determine the presence of underlying liver disease. Transhepatic portal venography represents a relatively more invasive approach to portal vein aneurysm imaging, but provides excellent definition of portal venous anatomy and demarcation of inflow and outflow portal venous and mesenteric venous vasculature, which is essential in potential aneurysm treatment planning.

While most portal vein aneurysms are asymptomatic, some present with abdominal pain [17]. The risk of complications from portal vein aneurysms is low [18]. Potential complications of portal vein aneurysms include portal system thrombosis, portal hypertension, and aneurysm rupture [5, 17, 19]. Compression of the common bile duct may result in obstructive jaundice [20]. In the absence of clinical symptoms and intrinsic liver disease with portal hypertension, most portal vein aneurysms do not require treatment. If incidentally discovered, close imaging follow-up of portal vein aneurysms may be recommended. If aneurysm growth or aneurysm related complications develop, treatment is advised [18]. Therapies include both medical and surgical approaches. Medical therapy may consist of anticoagulation for treatment of portal vein thrombosis. Surgical treatment options include aneurysmorrhaphy, portocaval shunt, and mesocaval shunt. Aneurysmorrhaphy has the benefit of maintaining portal blood flow, but requires potentially dangerous aneurysm manipulation. Portosystemic shunting avoids aneurysm mobilization, but may result

Extrahepatic Portal Vein Aneurysm

in morbidities such as encephalopathy.

Given the ascension of minimal invasive therapies during recent years, endovascular approaches to the treatment of portal vein aneurysms may be considered. Interventional radiologic approaches to portal vein aneurysm therapy include including stent-graft exclusion. Extensive treatment planning is necessary prior to considering endovascular therapy, however, including assessment of inflow and outflow vessel size, evaluation of stent landing zones, need for exclusion of mesenteric or splenic venous branch vessels, and need for adjunctive embolization, such as splenic arterial and venous embolization to prevent endoleak. In our case, stent-graft insertion would be challenging given size incompatibility between the mesenteric and portal ends of the aneurysm. Further complicating matters is involvement of both the splenic and superior mesenteric veins, requiring exclusion of one vessel during stent-graft insertion (assuming that a bifurcated device is not used) with possible embolization to avoid endoleak. As a precaution, it should be noted that such a complex procedure is best performed by operators familiar with endovascular techniques of transvenous and transhepatic portal access, stent deployment, and embolotherapy in order to avoid complicating circumstances with bleeding complications, stent maldeployment, or non-target embolization.

References

1. Calligaro KD, Ahmad S, Dandora R, et al. Venous aneurysms: surgical indications, and review of the literature. *Surgery* 1995; 117:1-6. [PubMed]
2. Feliciano PD, Cullen JJ, Corson JD. The management of extrahepatic portal vein aneurysms: observe or treat? *HPB Surgery* 1996; 10:113-6. [PubMed]
3. Fulcher A, Turner M. Aneurysms of the portal vein and superior mesenteric vein. *Abdom Imaging* 1997; 22:287-92. [PubMed]
4. Ohnami Y, Ishida H, Konno K, et al. Portal vein aneurysm: report of six cases and review of the literature. *Abdom Imaging* 1997; 22:281-6. [PubMed]
5. López-Machado E, Mallorquín-Jiménez F, Medina-Benítez A, et al. Aneurysms of the portal venous system: ultrasonography and CT findings. *Eur J Radiol* 1998; 26:210-4. [PubMed]
6. Atasoy KC, Fitoz S, Akyar G, et al. Aneurysms of the portal venous system. Gray-scale and color Doppler ultrasonographic findings with CT and MRI correlation. *Clin Imaging* 1998; 22:414-7. [PubMed]
7. Tsukuda S, Sugimoto E, Watabe T, et al. A case of extrahepatic portal vein aneurysm with massive thrombosis: diagnosis with reconstruction images from helical CT scans. *Radiat Med* 1998; 16:301-3. [PubMed]
8. Blasbalg R, Yamada RM, Tiferes DA. Extrahepatic portal vein aneurysms. *AJR Am J Roentgenol* 2000;174:877. [PubMed]
9. Lau H, Chew DK, Belkin M. Extrahepatic portal vein aneurysm: a case report and review of the literature. *Cardiovasc Surg* 2002; 10:58-61. [PubMed]
10. Barzilai R, Kleckner MS Jr. Hemocholecyst following ruptured aneurysm of portal vein. *AMA Arch Surg* 1956 Apr; 72(4):725-7. [PubMed]
11. Doust BD, Pearce JD. Gray-scale ultrasonic properties of the normal and inflamed pancreas. *Radiology* 1976; 120:653-7. [PubMed]
12. Gallagher DM, Leiman S, Hux CH. In utero diagnosis of a portal vein aneurysm. *J Clin Ultrasound* 1993; 21:147-51. [PubMed]
13. Hagiwara H, Kasahara A, Kono M, et al. Extrahepatic portal vein aneurysm associated with a tortuous portal vein. *Gastroenterology* 1991; 100:818-21. [PubMed]
14. Leonsins AJ, Siew S. Fusiform aneurysmal dilatation of the portal vein. *Postgrad Med J* 1960; 36:570-4. [PubMed]
15. Atasoy KC, Fitoz S, Akyar G, et al. Aneurysms of the portal venous system. Gray-scale and color Doppler ultrasonographic findings with CT and MRI correlation. *Clin Imaging* 1998; 22: 414-7. [PubMed]

Extrahepatic Portal Vein Aneurysm

16. Tsukuda S, Sugimoto E, Watabe T, et al. A case of extrahepatic portal vein aneurysm with massive thrombosis: diagnosis with reconstruction images from helical CT scans. *Radiat Med* 1998; 16:301-3. [PubMed]
17. Thomas TV. Aneurysm of the portal vein, report of two cases, one resulting in thrombosis and spontaneous rupture. *Surgery* 1967; 61:550-5. [PubMed]
18. Ozbek SS, Killi MR, Pourbagher MA, et al. Portal venous system aneurysms, report of five cases. *J Ultrasound Med* 1999; 18:417-22. [PubMed]
19. Okur N, Inal M, Akgül E, Demircan O. Spontaneous rupture and thrombosis of an intrahepatic portal vein aneurysm. *Abdom Imaging* 2003; 28:675-7. [PubMed]
20. Sedgwick CE. Cisternal dilatation of portal vein associated with portal hypertension and partial biliary obstruction. *Lahey Clin Bull* 1960; 11:234-7. [PubMed]