

Epidermoid Cyst of the Testicle

Mahesh M. Thapa, M.D., Sumit Pruthi, M.D., and Gisele E. Ishak, M.D.

We describe the case of a 13-year-old boy with testicular epidermoid cyst who presented with a painless testicular mass. Epidermoid cyst of the testis is a benign, non-teratomatous tumor. It is often possible to make the diagnosis preoperatively, combining typical sonographic features with normal biochemical tumor markers. Preoperative diagnosis will allow for testis-sparing surgery and prevent unnecessary orchiectomy.

Case Report

A 13-year-old boy was referred to our hospital for evaluation of a left testicular mass, noted during a recent physical examination. Patient denied any pain and first noticed the mass himself two weeks prior. There was no history of trauma. Patient's past medical and surgical history was unremarkable. He was not taking any medication and his birth history was normal. Physical exam was significant for a firm, intratesticular mass at the posterior inferior aspect of the left gonad. There was no inguinal lymphadenopathy. Laboratory evaluation included beta-human chorionic gonadotropin (beta-HCG), lactate dehydrogenase (LDH), and alpha-feto-protein (AFP), all of which were normal.

Testicular ultrasound (Fig. 1) revealed a circumscribed, heterogeneous, predominantly hypoechoic mass

in the left testis. Several non shadowing hyperechoic foci in the periphery of the mass were identified, thought to represent fat or microscopic calcifications. Portions of the mass had a lamellated appearance with concentric rings of alternating echogenicity. There was no vascular flow detected on color Doppler imaging within the mass. The overall volume of the left testis was similar to the right. Epididymis was normal and there was no hydrocele or varicocele.

Given the characteristic ultrasound findings and the normal laboratory tumor markers, patient was taken to the operating room with a preoperative diagnosis of epidermoid cyst. A partial orchiectomy was performed. The lesion was sent for frozen analysis, confirming the diagnosis of epidermoid cyst. Microscopic analysis revealed normal testicular parenchyma with an area of squamous epithelium and fragments of sloughed keratin (Fig. 2). Patient tolerated the procedure well, and there were no complications.

Citation: Thapa MM, Pruthi S, Ishak GE. Epidermoid cyst of the testicle. *Radiology Case Reports*. [Online] 2009;4:275.

Copyright: © 2009 The Authors. This is an open-access article distributed under the terms of the Creative Commons Attribution-NonCommercial-NoDerivs 2.5 License, which permits reproduction and distribution, provided the original work is properly cited. Commercial use and derivative works are not permitted.

Mahesh M. Thapa, M.D. (Email: thapamd@u.washington.edu), Sumit Pruthi, M.D., and Gisele E. Ishak, M.D., are in the Department of Radiology, Seattle Children's Hospital and University of Washington, Seattle WA 98105, United States of America.

Published: May 31, 2009

DOI: 10.2484/rcr.v4i2.275

Discussion

Epidermoid cyst of the testis is an intraparenchymal cyst filled with keratin and contained within a fibrous capsule. It is lined by squamous epithelium and does not contain teratomatous elements or cutaneous

Epidermoid Cyst of the Testicle

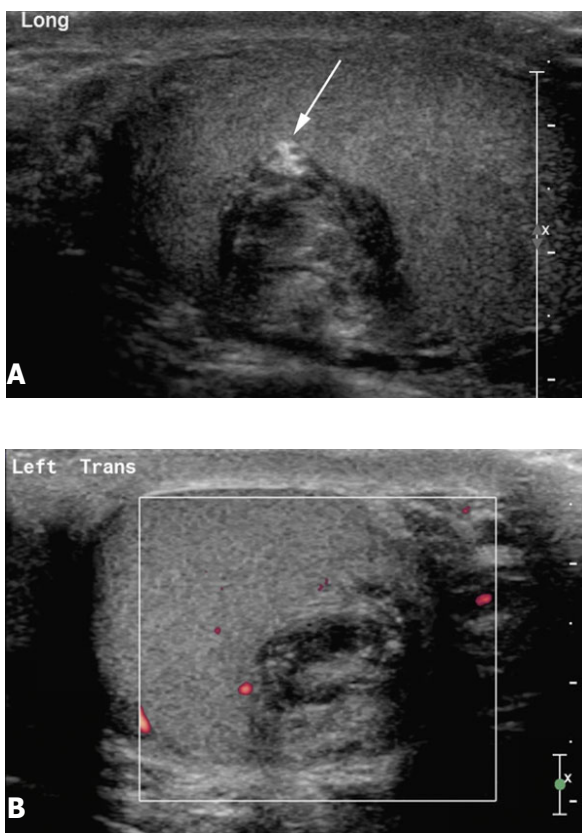


Figure 1. 13-year-old boy with epidermoid cyst of the testicle. **A**, Longitudinal ultrasound of the left testis demonstrates a well circumscribed heterogeneous mass with a nonshadowing hyperechoic focus in the periphery (arrow) which may represent fat or microscopic calcification. Portions of the mass have a lamellated appearance with concentric rings of alternating echogenicity. **B**, Color Doppler image through another portion of the mass shows no vascular flow within the lesion.

adnexal structures [1]. Commonly found in the brain and meninges, epidermoid cysts are benign epithelial tumors. They are rare in the testis and comprise only 1 to 2 percent of all intratesticular tumors [1-3]. Most patients are non-white males, and they are in their 2nd or 3rd decade of life at time of diagnosis [2, 4]. Patients usually present with nontender testicular enlargement or mass. Originally, epidermoid cysts were thought to be a monodermal development of teratoma, implying a direct relation to a single cell line and a malignant or premalignant potential [2, 5]. However, now epider-

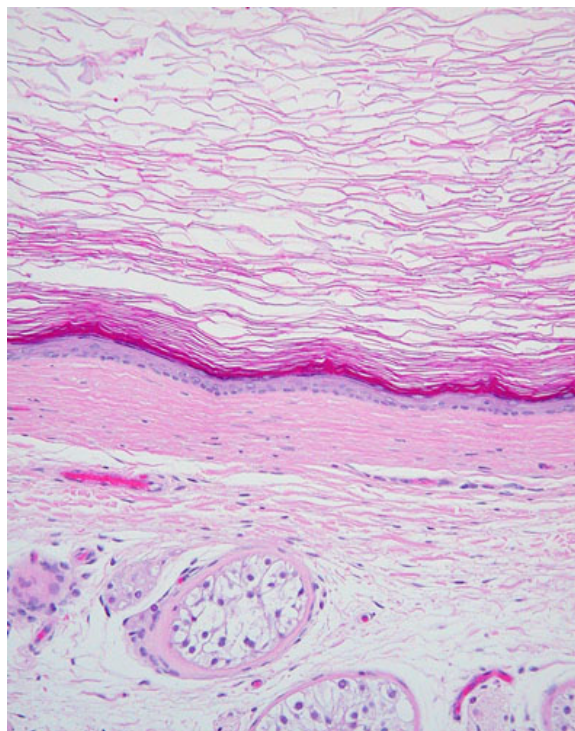


Figure 2. 13-year-old boy with epidermoid cyst of the testicle. Photomicrograph of resected cyst demonstrates keratinized material within the lumen (*). The cyst is lined by squamous epithelium (arrow). Normal seminiferous tubules can also be identified (arrow heads). (Hematoxylin-Eosin, original magnification x 100).

moid cysts are considered to be a non-teratomatous benign tumor because histologic analysis of 10 EC found no evidence of surrounding malignancy such as intratubular atypical germ cells that are frequently seen in tissue of patients with teratomas [3, 6]. Both enucleation and orchiectomy have been performed to remove the lesion [3, 7]. However, because the clinical course of the disease is universally favorable and no recurrences or metastasis have been observed, conservative testis-sparing surgery is recommended as the treatment of choice [8, 9].

The ultrasonographic characteristics of epidermoid cysts of the testis have excellent correlation with gross pathological findings. Generally, all lesions are intratesticular, well-demarcated, and avascular without peripheral stromal abnormalities [3]. Lesions may be bilateral

Epidermoid Cyst of the Testicle

and/or multiple and internal concentric laminations (“onion ring”) have also been described [10-13]. Calcifications may be present in the wall or within the cyst or in a target pattern [14-16].

Epidermoid cyst of the testis is an uncommon tumor, especially in children. However, it should be part of the differential diagnosis when considering childhood testicular masses. Because surgical approach and management depend on preoperative radiological findings [9] and biochemical markers, it is important to identify this rare tumor in order to prevent aggressive surgery, such as orchiectomy.

References

1. Price EB, Jr. Epidermoid cysts of the testis: a clinical and pathologic analysis of 69 cases from the testicular tumor registry. *J Urol* 1969 Dec;102(6):708-13. [PubMed]
2. Shah KH, Maxted WC, Chun B. Epidermoid cysts of the testis: a report of three cases and an analysis of 141 cases from the world literature. *Cancer* 1981 Feb 1;47(3):577-82. [PubMed]
3. Dieckmann KP, Loy V. Epidermoid cyst of the testis: a review of clinical and histogenetic considerations. *Br J Urol* 1994 Apr;73(4):436-41. [PubMed]
4. Malek RS, Rosen JS, Farrow GM. Epidermoid cyst of the testis: a critical analysis. *Br J Urol* 1986 Feb;58(1):55-9. [PubMed]
5. Archley JT, Dewbury KC. Ultrasound appearances of testicular epidermoid cysts. *Clin Radiol* 2000 Jul;55(7):493-502. [PubMed]
6. Jacobsen GK, Henriksen OB, von der Maase H. Carcinoma in situ of testicular tissue adjacent to malignant germ-cell tumors: a study of 105 cases. *Cancer* 1981 Jun 1;47(11):2660-2. [PubMed]
7. Heidenreich A, Engelmann UH, Vietsch HV, Derschum W. Organ preserving surgery in testicular epidermoid cysts. *J Urol* 1995 Apr;153(4):1147-50. [PubMed]
8. Lev R, Mor Y, Leibovitch I, et al. Epidermoid cyst of the testis in an adolescent: Case report and review of the evolution of the surgical management. *J Pediatr Surg* 2002 Jan;37(1):121-3. [PubMed]
9. Fujino J, Yamamoto H, Kasaki Y, et al. Epidermoid cyst: rare testicular tumor in children. *Pediatr Radiol* 2004 Feb;34(2):172-4. [PubMed]
10. Sanderson AJ, Birch BR, Dewbury KC. Case report: multiple epidermoid cysts of the testes--the ultrasound appearances. *Clin Radiol* 1995 Jun;50(6):414-5. [PubMed]
11. Strahlberg M, Brown JS. Concomitant bilateral epidermoid cysts of the testes. *J Urol* 1973 Mar;109(3):434-5. [PubMed]
12. Malvica RP. Epidermoid cyst of the testicle: an unusual sonographic finding. *AJR Am J Roentgenol* 1993 May;160(5):1047-8. [PubMed]
13. Eustace S, Graham D, Behan M, Smith JM. Ultrasonographic diagnosis and surgical enucleation of an epidermoid cyst of the testis. *Br J Urol* 1994 Oct;74(4):518-9. [PubMed]
14. Bahnson RR, Slasky BS, Ernstoff MS, Banner BF. Sonographic characteristics of epidermoid cyst of testicle. *Urology* 1990 Jun;35(6):508-10. [PubMed]
15. Cohen EL, Mandel E, Goodman JD, et al. Epidermoid cyst of testicle. Ultrasonographic characteristics. *Urology* 1984 Jul;24(1):79-81. [PubMed]
16. Maxwell AJ, Mamtora H. Sonographic appearance of epidermoid cyst of the testis. *J Clin Ultrasound* 1990 Mar-Apr;18(3):188-90. [PubMed]